

U. PORTO



FACULDADE DE MEDICINA
UNIVERSIDADE DO PORTO

MESTRADO INTEGRADO EM MEDICINA

2021/2022

Beatriz Vieira Cabral

Spontaneous keloids: a rare entity

Quelóides espontâneos: uma entidade rara

março, 2022

FMUP

U. PORTO

**FM
UP** FACULDADE DE MEDICINA
UNIVERSIDADE DO PORTO

Beatriz Vieira Cabral

Spontaneous keloids: a rare entity

Quelóides espontâneos: uma entidade rara

Mestrado Integrado em Medicina

Área: Cirurgia Plástica

Tipologia: Monografia

Trabalho efetuado sob a Orientação de:
Professor Doutor Ricardo José Moreira Horta Oliveira

Trabalho organizado de acordo com as normas da revista:
Journal of Plastic Reconstruction & Aesthetic Surgery

março, 2022

FMUP

Eu, Beatriz Vieira Cabral, abaixo assinado, nº mecanográfico 201304008, estudante do 6º ano do Ciclo de Estudos Integrado em Medicina, na Faculdade de Medicina da Universidade do Porto, declaro ter atuado com absoluta integridade na elaboração deste projeto de opção.

Neste sentido, confirmo que **NÃO** incorri em plágio (ato pelo qual um indivíduo, mesmo por omissão, assume a autoria de um determinado trabalho intelectual, ou partes dele). Mais declaro que todas as frases que retirei de trabalhos anteriores pertencentes a outros autores, foram referenciadas, ou redigidas com novas palavras, tendo colocado, neste caso, a citação da fonte bibliográfica.

Faculdade de Medicina da Universidade do Porto, 17/03/2022

Assinatura conforme cartão de identificação:

Beatriz Vieira Cabral

NOME

Beatriz Vieira Cabral

NÚMERO DE ESTUDANTE

201304008

E-MAIL

beatrizvc1995@hotmail.com

DESIGNAÇÃO DA ÁREA DO PROJECTO

Cirurgia Plástica

TÍTULO ~~DISSERTAÇÃO~~/MONOGRAFIA (riscar o que não interessa)

Spontaneous keloids: a rare entity

ORIENTADOR

Ricardo José Moreira Horta Oliveira

COORIENTADOR (se aplicável)

ASSINALE APENAS UMA DAS OPÇÕES:

É AUTORIZADA A REPRODUÇÃO INTEGRAL DESTA OBRA APENAS PARA EFEITOS DE INVESTIGAÇÃO, MEDIANTE DECLARAÇÃO ESCRITA DO INTERESSADO, QUE A TAL SE COMPROMETE.	<input type="checkbox"/>
É AUTORIZADA A REPRODUÇÃO PARCIAL DESTA OBRA (INDICAR, CASO TAL SEJA NECESSÁRIO, Nº MÁXIMO DE PÁGINAS, ILUSTRAÇÕES, GRÁFICOS, ETC.) APENAS PARA EFEITOS DE INVESTIGAÇÃO, MEDIANTE DECLARAÇÃO ESCRITA DO INTERESSADO, QUE A TAL SE COMPROMETE.	<input type="checkbox"/>
DE ACORDO COM A LEGISLAÇÃO EM VIGOR, (INDICAR, CASO TAL SEJA NECESSÁRIO, Nº MÁXIMO DE PÁGINAS, ILUSTRAÇÕES, GRÁFICOS, ETC.) NÃO É PERMITIDA A REPRODUÇÃO DE QUALQUER PARTE DESTA OBRA.	<input checked="" type="checkbox"/>

Faculdade de Medicina da Universidade do Porto, 17/03/2022

Assinatura conforme cartão de identificação: Beatriz Vieira Cabral

Trabalho

Spontaneous keloids: a rare entity

Beatriz Cabral MD¹, Ricardo Horta PhD^{2,3}

1 Faculty of Medicine, University of Porto, Portugal

2 Department of Surgery and Physiology, Faculty of Medicine of University of Porto, Portugal

3 Department of Plastic and Reconstructive Surgery, Centro Hospitalar São João, Porto, Portugal

Corresponding author:

Beatriz Cabral, MD

Address: Faculty of Medicine, University of Porto, Portugal

Avenida Prof. Hernâni Monteiro, 4200-319 Porto, Portugal

Fax: 00351225025766

Telephone number: 00351225512100

E-mail: beatrizvc1995@hotmail.com

Disclosures: None of the authors has conflict of interest with the submission.

Abstract

Purpose: Keloid scars are a benign fibroproliferative disorder resulting from tissue scar inflammation and abnormal collagen accumulation. Spontaneous keloids occur in the absence of an original traumatic condition, with reported cases associated with several genetic syndromes and a positive family history. This review aims to gather these existing cases, organizing them according to their possible etiology and used treatments.

Methods: This review was conducted using PubMed and Web of Science, by using the query (“spontaneous keloids” OR “idiopathic keloids”). No type of filter was applied in the search due to the scarcity of published cases and rarity of this scarring disorder. All case reports and studies related to spontaneous keloids were included and all cases associated with trauma were excluded. In addition, two case reports of this type of keloids were also included.

Results: It was possible to verify an association between spontaneous keloids and some genetic disorders. However, there were cases where individuals are completely healthy. Regarding the types of treatment used, it was shown that most keloids remain highly refractory to therapy with high rates of recurrence.

Conclusion: Idiopathic keloids are an extremely rare condition whose exact etiology is often difficult to determine, although in certain cases it is possible to verify a probable genetic influence on the origin of this type of scar. Despite its refractoriness, nowadays the combination of surgery and postoperative radiotherapy has shown excellent results.

Keywords: Spontaneous keloids; Fibroproliferative disorder; Genetic susceptibility; Trauma; Benign

Introduction

Keloid is a fibroproliferative skin disorder resulting from an abnormal healing process that generates chronic wound inflammation and a continuous deposition of collagen fibers. (1) The distinguishing feature of keloids from hypertrophic scars is their tendency to invade the surrounding skin, extending beyond the limits of the original wound. (2) They may appear several years after the initial trauma, grow slowly, and almost never regress. (3)

The most common areas of the body for the appearance of keloids are those that have a strong or repetitive stretching of the skin, such as the anterior chest, shoulder and ears, being a rare occurrence in the scalp and anterior tibia. (4)

Keloids can occur in people of any ethnicity, however they are more commonly seen in Hispanic, Asian (5) and African descent individuals, with an incidence between 6-16% in the latter. (6) One study showed a correlation between sun exposure and the development of these scars, with the higher the Fitzpatrick phototype, the greater the propensity for the development of keloids. (5)

Although much of the literature argues that keloids affect men and women equally and that there are no significant differences regarding the average age of onset, women have twice the prevalence at almost all ages, including before the age of 15 years old. (1)

Keloids are usually the result of trauma but can also be associated with genetic conditions or a positive family history. Much more rarely, they can also arise spontaneously, when there is no history of trauma or surgery. (7)

Regarding the histopathological characteristics, keloid scars have a specific presentation, demonstrating an excessive accumulation of hardened collagen fibers (mostly type I) (8) arranged in clusters and hyalinized.

Asymptomatic or associated with itching, pain and deformation, keloids can lead to a disabling situation both physically and psychologically, with a great impact on the patients' quality of life. (6) It should be noted that although keloids are not considered malignant conditions, some articles argue that they have some cancer-like characteristics (9) that may underlie clinically more aggressive and disfiguring keloids.

This fibroproliferative disorder may have its origins in several systemic and local factors, and its pathophysiology is complex and still poorly understood. According to existing knowledge, scar growth appears to be driven by inflammation in the reticular dermis, with consequent accumulation of inflammatory cells and fibroblasts in the scar area. This leads to increased levels of pro-inflammatory cytokines such as IL-6 and TNF- α , promoting a chronic inflammation that is a precursor to the increase in keloid size. (3) Systemic factors such as adolescence and pregnancy, due to hormonal changes and the vasodilator effect of estrogen, will exacerbate local inflammation. Local risk factors such as prolonged healing, wound depth and skin tension can also contribute to this abnormal healing process. (4)

In the literature, there are several available treatments for keloids, including medical compressive ointments, intralesional injections of corticosteroids, non-steroidal products, surgical excision, laser treatment, intralesional cryotherapy and postoperative radiotherapy. A combination therapy with surgical excision followed by radiotherapy has emerged as a new method of choice, with a lower recurrence rate (between 6-27%). (2) It is also important to highlight the development of new therapies in the field of genetics, epigenetics and stem cell therapy, which have shown promising results. However, despite this variety of therapeutic options, keloids remain highly refractory lesions, requiring a search for more effective therapies. (8)

The purpose of this review article is to collect and compile the reported cases of spontaneous keloids existing in the literature, organizing them according to the existence of genetic susceptibility or other associated medical conditions. In addition, an analysis of the effectiveness of the therapies used in this case reports will be performed, as well as a brief review of treatment options of keloids. Therefore, it is intended to produce a clear review on reported spontaneous keloids, an extremely rare condition universally, with few published cases and many uncertainties to be clarified.

Methods

This review was conducted through a search using the online search engines PUBMED/MEDLINE and WEB OF SCIENCE. The query (“spontaneous keloids” OR “idiopathic keloids”) was used and, due to the rarity of this scarring disorder, the scarcity of existing cases in the literature and in order to assure a compilation of the largest number of case reports related to spontaneous keloids, no filter of any kind was applied in the search.

From this stage, all articles resulting from the search and freely accessible were analyzed and chosen after reading the title, abstract or full text.

Thus, all published and accessible case reports and studies performed on humans related to spontaneous keloids were included in this paper, excluding all cases associated with trauma.

In addition, two case reports of two women, one 54 years old and the other 82 years old were included in this review. The first case report is about idiopathic keloid scars located in the posterior region of the left auricle submitted to surgical excision followed by radiotherapy. The second case report portrays multiple thoracic keloids, which have not undergone any medical or surgical treatment.

Thus, we tried to encompass a set of articles that would allow the fulfilment of a paper as comprehensive as possible, enabling a global analysis of the spontaneous keloids possible etiologies and therapies used.

Results

Through the carried out search, it was possible to verify that the concrete etiology of spontaneous keloids is not yet fully known. However, it was possible to verify some conditions that may be present at its origin.

1. Possible etiologies of spontaneous keloids

With this work, an association between spontaneous keloids and some genetic syndromes became evident, which is confirmed by the current literature (Table 1).

On the one hand, Guleç et al. (10) reported a case of a six-year-old boy with Noonan Syndrome who was more prone to develop recurrent keloids on his right foot, which is uncommon in this type of patient. On the other hand, the Goeminne Syndrome represents a new syndrome associated with X, characterized by the presence of congenital muscular torticollis, cryptorchidism, pyelonephritis and extensive spontaneous keloids, as described in the article (11). Another genetic disorder appears depicted by Haugen and Bertelsen (12), which reported the case of a Norwegian family in which the mother and her two children have conjunctival-corneal dystrophy. In this family, there was a spontaneous emergence of keloid lesions on the hands and fingers in the children and associated with a history of minimal trauma in the mother's case. Also published was the case of a 36-year-old male with a new Filamin A mutation X-associated Syndrome, characterized by valvular heart disease, decreased mobility and spontaneous keloid scarring, in this case on the thighs, hips and back. (13) Additionally, a genetic disease that seems to favor the existence of a hereditary pattern in relation to keloids is X-associated recessive polyfibromatosis. One of the cases described a 40-year-old man with a keloids personal and family history, who suddenly developed multiple keloids on the trunk and extremities at age of 20. (15) There were also cases of Bethlem Myopathy in a 32-year-old woman and a 50-year-old man, both of whom developed spontaneous keloids on the shoulder. (16) A possible association also arises with Dupuytren's disease, in which the case of a 60-year-old man with a personal history of keloids is reported, who subsequently develops five more keloids, the latter without any history of trauma (17). Another genetic condition with

greater published scientific evidence is the Rubinstein-Taybi Syndrome, widely associated with idiopathic keloids (18) (19) (20). It is also important to mention the case of a seven-year-old boy with Dubowitz Syndrome who suddenly manifested multiple spontaneous keloids at the age of four, without any previous trauma. (21) Also of note is the case of a 27-year-old patient with syndromic facies and mental illness who developed keloids idiopathically at various sites on her body. (22)

Despite this relationship with genetically susceptible individuals, there are also cases of this type of keloid reported in individuals with allergic disease. A 34-year-old woman with a history of severe asthma and chronic idiopathic angioedema developed two keloids on her back, without any history of trauma, surgery, or acne (23). Another case report describes a 24-year-old woman with a history of childhood asthma, pollen allergy and nickel contact allergy, who developed four keloids on her back, spontaneously (24). It is also relevant to emphasize the importance of not forgetting connective tissue disorders such as keloid scleroderma (25) and nephrogenic systemic fibrosis (26), both associated with keloid-like lesions, which can confuse and delay the diagnosis of these pathologies.

Some articles also described multiple cases of idiopathic keloids in individuals without an existing medical condition (Table 2). Within these, there were cases of keloids that have grown in the most common body areas, but also in the labia majora, post-auricular region, cornea and below the nipple.

An observational case-control study involving 259 Syrian individuals with keloids showed that 34 of them developed keloids spontaneously, mostly on the shoulders and the presternal region. Moreover, it also revealed a statistically significant association between these and blood group type A (34). Another observational case-control study involving 88 Iraqi patients with keloids revealed that 34% of them had no history of trauma, and grew mostly solitary and on the upper body. (35)

2. Therapies used

Regarding the different types of therapies, the use of various treatment methodologies was evident, from surgical excision in monotherapy or combined with postoperative radiotherapy, intralesional injections of corticosteroids, cryotherapy, silicone gel and occlusive

dressings. As corroborated by existing knowledge, none of these therapies has yet demonstrated a fully proven success, as keloids are highly refractory to current therapies, with high recurrence rates.

However, and although little information is available on the cases examined, it was possible to verify different efficacy rates between the treatments used. The use of low dose UVA-1 phototherapy showed a reduction of itching and discomfort, flattening and softening of keloids, although it did not cause aesthetic or erythema improvement. (27) Despite this, an aesthetic and symptom improvement was seen in one patient after surgical excision followed by electrom beam radiotherapy with a dose of 9 Gy. (28) Note that, although uncommon, there were no signs of recurrence six months after surgical excision of the post-auricular keloid used as monotherapy. (29)

In one patient, the use of surgical excision followed by radiotherapy accompanied by compression techniques showed a slight recurrence after three months. Subsequently, intralesional Triamcinolone Acetonide was used with only partially satisfactory result, with atrophy of half the lesions and partial regression of the other half. (32) In the same patient, the use of surgical excision in other lesions followed by intralesional injection of Triamcinolone Acetonide and radiotherapy showed no signs of recurrence after three years of follow-up. (32) In the remaining cases, the use of surgical excision in monotherapy (10), local radiotherapy alone (12) (20), intralesional and local corticosteroid injection (13) (15) (20), cryotherapy (17) and silicone gel (31) have not demonstrated therapeutic success.

It is important to note that rare cases of keloids that regressed spontaneously and relatively quickly (five years after their onset) with no signs of recurrence afterwards, have been described. (36) (37) Therefore, these articles provide encouraging knowledge regarding a possible cure of this pathology.

In the following, 2 reported cases of idiopathic keloids that have not yet been published in the literature will be presented.

3. Case Report 1

A 54-year-old Caucasian female with an idiopathic keloid in the posterior region of the left auricle underwent surgical excision followed by radiation therapy after two previous unsuccessful removal attempts. (Fig. 1 A and B) 3 months following the procedure, the patient showed no evidence of recurrence and minimal hyperpigmentation. (Fig. 1 C and D)

4. Case Report 2

An 82-year-old Caucasian female developed several spontaneous thoracic keloids with no history of surgery or trauma. Patient did not want surgical excision. (Fig. 2 A and B)

Discussion

As far as genetic syndromes are concerned, there are some possible explanations that try to justify their relationship with the emergence of idiopathic keloids. About Corneal Connective Dystrophy, there seems to be a congenital defect capable of affecting some growth factors and, consequently, causing a dysregulation of connective tissue growth. (12) In turn, in the Filamin A G1576R Mutation Syndrome, the reason for the appearance of keloids may be due to a disturbance of the TFB- β signaling, which has been proven to be overregulated in these scars. (13) In Rubinstein-Taybi Syndrome, there are mutations in CREBBP, which is a co-activator of the Sma and Mad protein. These, once activated, also have a regulatory role in the activation of TGF- β . (38) In turn, in Dupuytren's contracture there is an accumulation of type III collagen, which is also present in keloids, favouring a possible common molecular origin. (15) Patients with Bethlehem myopathy show mutations in type VI collagen, which is important for skin integrity, wound healing and tissue repair. Therefore, changes in this collagen subtype appear to alter the structure of collagen, making the skin more susceptible to keloid formation. (39)

The immune system plays a key role in the normal healing of the skin, but also in abnormal healing processes, such as keloids. These have a high number of mast cells, with a high concentration of histamine and consequent elevation of Immunoglobulin E. It is, therefore, interesting to note that patients with keloid scars are more likely to have allergic symptoms and vice versa. (24)

Keloid scarring occurs due to excessive deposition of extracellular matrix in the skin, being the major constituent involved collagen produced by fibroblasts. Any skin lesion can lead to the activation of these cells through multiple cytokines and growth factors such as TGF- β , PDGF, VEGF, IL-6, TNF- α , INF- β , among others. (40) The continuous activation of fibroblasts and, consequently, an increase in the amount of collagen, leads to the growth of the keloid, which will only be resolved with the removal of this fibrotic tissue.

The drugs that can currently be used are based on three main principles. If we look at keloids as localized tumors, chemotherapy can be used (the most commonly used agents being

Bleomycin, 5-Fluorouracil, and Mitomycin). (8) In turn, if keloids are seen as inflammatory lesions, corticosteroids can be used (with Triamcinolone Acetonide being applied more frequently) and Botulinum Toxin A. (8) In addition, there also appears to be benefit with some systemic therapies such as those used for hypertension and treatment of breast cancer. (8) Some immunotherapies (such as Tacrolimus, Imiquimod, and Interferons) and volume-reducing therapies (such as intralesional collagenase injections) have been clinically tested, and genetic, epigenetic, and stem cell-based therapies are also in preclinical phase.

It should be noted that corticosteroid injections are often used as first-line therapy in the treatment of keloids, with a response rate varying between 50-100% and a recurrence rate between 9-50%. (41) (42) However, they may have some adverse effects such as pain, hypo or hyperpigmentation, skin atrophy and telangiectasia. (8)

Several studies have shown that surgical excision used as monotherapy is associated with a high recurrence rate, which can vary between 50-80%, and should be mostly avoided. (43)

In order to reduce complications and refractoriness of the lesions, the use of a combination therapy with postoperative radiotherapy is currently advocated, preferably using electron beam radiation. (8) (43) There is no universally accepted dose for the treatment of keloids, and a dose-dependent protocol should always be used on the most appropriate body area. In benign diseases, studies show that an intermediate dose of radiotherapy (between 3-50 Gy, with an average of approximately 20 Gy) can be effective, with minimal or rare adverse effects. (44) A retrospective study analyzed 124 patients with 250 keloids who were treated with postoperative radiotherapy and showed that after a median follow-up period of 40 months the overall recurrence rate for all lesions was 5.6%. (41) The group of patients with lesions treated with 20 Gy had a recurrence rate of 1.6% while the group treated with <20 Gy had 9.6% (with an odds ratio of 0.16 (confidence interval 0.036-0.75, $P = 0.02$). (41)

The cutaneous complications of radiotherapy (such as erythema, atrophy and telangiectasia) should be minimized by protecting more sensitive organs such as the thyroid and mammary glands (8), and in individuals aged <20 years, due to greater radiosensitivity, this should be avoided. (43) It should also be noted that the risk of radiation-induced cancer should not be overlooked, which, despite being very small, must be taken into account. (44)

In summary, it is evident that idiopathic keloids are an extremely rare condition in which it is often difficult to determine its exact etiology due to the lack of relationship with any traumatic or medical condition. However, in certain cases, it is possible to attribute them to certain genetic syndromes, which shows a possible genetic influence on the origin of this type of scar. Regarding treatment, despite the numerous existing and developing therapies, keloids remain a condition that is highly refractory to therapy, and nowadays a combination of surgery and postoperative radiotherapy is advocated, and the risks and benefits of its use should always be very carefully considered.

References

1. Noishiki C, Hayasaka Y, Ogawa R. Sex Differences in Keloidogenesis: An Analysis of 1659 Keloid Patients in Japan. *Dermatol Ther (Heidelb)*. 2019;9(4):747-754.
2. Petrou IG, Jugun K, Rüegg EM, Zilli T, Modarressi A, Pittet-Cuénod B. Keloid treatment: what about adjuvant radiotherapy? *Clin Cosmet Investig Dermatol*. 2019;12:295-301.
3. Karppinen SM, Heljasvaara R, Gullberg D *et al*. Toward understanding scarless skin wound healing and pathological scarring [version 1; peer review: 2 approved]. *F1000Research* 2019.
4. Tsai CH, Ogawa R. Keloid research: current status and future directions. *Scars Burn Heal*. 2019;5:2059513119868659.
5. Hochman B, Farkas CB, Isoldi FC, Ferrara SF, Furtado F, Ferreira LM. Distribuição de quelóide e cicatriz hipertrófica segundo fotótipos de pele de Fitzpatrick. *Revista Brasileira de Cirurgia Plástica*. 2012;27:185-9.
6. Lim KH, Itinteang T, Davis PF, Tan ST. Stem Cells in Keloid Lesions: A Review. *Plast Reconstr Surg Glob Open*. 2019;7(5):e2228.
7. Jfri A, Alajmi A. Spontaneous Keloids: A Literature Review. *Dermatology*. 2018;234(3-4):127-130.
8. Huang C, Liu L, You Z, Du Y, Ogawa R. Managing keloid scars: From radiation therapy to actual and potential drug deliveries. *Int Wound J*. 2019;16(3):852-859.
9. Tan S, Khumalo N, Bayat A. Understanding Keloid Pathobiology From a Quasi-Neoplastic Perspective: Less of a Scar and More of a Chronic Inflammatory Disease With Cancer-Like Tendencies. *Front Immunol*. 2019;10:1810.
10. Güleç AT, Karaduman A, Seçkin D. Noonan syndrome: a case with recurrent keloid formation. *Cutis*. 2001;67(4):315-6.
11. Goeminne L. A new probably X-linked inherited syndrome: congenital muscular torticollis, multiple keloids cryptorchidism and renal dysplasia. *Acta Genet Med Gemellol (Roma)*. 1968;17(3):439-67.
12. Haugen OH, Bertelsen T. A new hereditary conjunctivo-corneal dystrophy associated with dermal keloid formation. Report of a family. *Acta Ophthalmol Scand*. 1998;76(4):461-5.

13. Atwal PS, Blease S, Braxton A, Graves J, He W, Person R, Slattery L, Bernstein JA, Hudgins L. Novel X-linked syndrome of cardiac valvulopathy, keloid scarring, and reduced joint mobility due to filamin A substitution G1576R. *Am J Med Genet A*. 2016;170A(4):891-5.
14. Yonan Y, DiCaudo D, Aslam F. Aggressive polyfibromatosis with spontaneous keloid formation and erosive arthropathy. *J Am Acad Dermatol*. 2018;79(3):AB32
15. Ly L, Winship I. X-linked recessive polyfibromatosis manifesting with spontaneous keloid scars and Dupuytren's contracture. *Australas J Dermatol*. 2012;53(2):148-50.
16. Collins J, Foley AR, Straub V, Bönnemann CG. Spontaneous keloid formation in patients with Bethlem myopathy. *Neurology*. 2012;79(21):2158.
17. González-Martínez R, Marín-Bertolín S, Amorrortu-Velayos J. Association between keloids and Dupuytren's disease: case report. *Br J Plast Surg*. 1995;48(1):47-8.
18. Shilpashree P, Jaiswal AK, Kharge PM. Keloids: an unwanted spontaneity in rubinstein-taybi syndrome. *Indian J Dermatol*. 2015;60(2):214.
19. Bansal S, Relhan V, Garg VK. Rubinstein-Taybi syndrome: A report of two siblings with unreported cutaneous stigmata. *Indian J Dermatol Venereol Leprol* 2013;79:714-717
20. Goodfellow A, Emmerson RW, Calvert HT. Rubinstein-Taybi syndrome and spontaneous keloids. *Clin Exp Dermatol*. 1980;5(3):369-70.
21. Paradisi M, Angelo C, Conti G et al. Dubowitz syndrome with keloidal lesions. *Clin Exp Dermatol*. 1994;19(5):425-7.
22. Jfri A, Rajeh N, Karkashan E. A Case of Multiple Spontaneous Keloid Scars. *Case Rep Dermatol* 2015;7:156-160.
23. McCabe J, Blades Z, McGrath E. A spontaneous skin lesion. *CMAJ*. 2008;179(12):1297-1299
24. Oittinen, H, O'Shaughnessy M. Multiple Nonsyndromic Spontaneous Keloids in Allergic Disease. *Plastic and Reconstructive Surgery*. 2007;119(2), 762-763
25. Heath CR, David JN, Taylor SC. Nodular scleroderma presenting as multiple spontaneous keloidal scars. *J Am Acad Dermatol*. 2012;66(6):e245-6.
26. Bremmer M, Deng A, Martin DB. Spontaneous eruptive keloid-like cutaneous lesions in a renal transplant patient: a form of nephrogenic systemic fibrosis? *J Dermatolog Treat*. 2009;20(1):63-6.

27. Cuenca-Barrales C, Aneiros-Fernández J, Pérez-López I, Rodríguez-Pérez J, Ruiz-Villaverde R, Espelt-Otero JL. Histological Changes Related to Symptomatic Improvement of Spontaneous Keloids Treated with a Low-Dosage Regimen of UVA-1 Phototherapy. *Dermatopathology (Basel)*. 2020;7(3):53-56.
28. Zhang W, Wang X, Huang J, Dong W, Long X. Spontaneous symmetrical giant keloids at the bilateral labia majora: a case report. *Journal of International Medical Research*. 2020; 48(4): 1–6.
29. Monarca C, Maruccia M, Palumbo F, Parisi P, Scuderi N. A rare case of postauricular spontaneous keloid in an elderly patient. *In Vivo*. 2012;26(1):173-5.
30. Fukuda K, Chikama T, Takahashi M, Nishida T. Long-term follow-up after lamellar keratoplasty in a patient with bilateral idiopathic corneal keloid. *Cornea*. 2011;30(12):1491-4.
31. Kerfant N, Gasnier P, Bolorchi A, Uguen A, Hu W. À propos d'un cas exceptionnel de chéloïdes spontanées. *Annales de Chirurgie Plastique Esthétique*, 2011;56(4):339-341.
32. Bukvić-Mokos Z, Lipozencić J, Marinović B. Different therapeutic modalities in a patient with multiple spontaneously developed keloids--a case report. *Coll Antropol*. 2006;30(4):941-4.
33. Finlay GH, Stoughton RB. Spontaneous keloid with unusual histologic features. *AMA Arch Derm*. 1955;71(5):599-601.
34. Shaheen A, Khaddam J, Kesh F. Risk factors of keloids in Syrians. *BMC Dermatol*. 2016;16(1):13..
35. Sharquie KE, Al-Dhalimi MA. Keloid in Iraqi patients: a clinicohistopathologic study. *Dermatol Surg*. 2003;29(8):847-51.
36. Smith OJ, McGrouther DA. The natural history and spontaneous resolution of keloid scars. *J Plast Reconstr Aesthet Surg*. 2014;67(1):87-92.
37. Alonso PE, Rioja LF. Spontaneous resolution of a keloid. *Plast Reconstr Surg*. 2011;128(2):98e-99e.
38. van de Kar AL, Houge G, Shaw AC et al. Keloids in Rubinstein-Taybi syndrome: a clinical study. *Br J Dermatol*. 2014;171(3):615-21.
39. Echeverría C, Diaz A, Suarez B et al. Keloids, Spontaneous or After Minor Skin Injury: Importance of Not Missing Bethlem Myopathy. *Acta Derm Venereol*. 2017;97(2):297-298.

40. Andrews JP, Marttala J, Macarak E, Rosenbloom J, Uitto J. Keloids: The paradigm of skin fibrosis - Pathomechanisms and treatment. *Matrix Biol.* 2016;51:37-46.
41. Renz P, Hasan S, Gresswell S, Hajjar RT, Trombetta M, Fontanesi J. Dose Effect in Adjuvant Radiation Therapy for the Treatment of Resected Keloids. *Int J Radiat Oncol Biol Phys.* 2018;102(1):149-154.
42. Rabello FB, Souza CD, Farina Júnior JA. Update on hypertrophic scar treatment. *Clinics (Sao Paulo).* 2014;69(8):565-573.
43. Ogawa R, Tosa M, Dohi T, Akaishi S, Kuribayashi S. Surgical excision and postoperative radiotherapy for keloids. *Scars Burn Heal.* 2019;5:2059513119891113.
44. McKeown SR, Hatfield P, Prestwich RJ, Shaffer RE, Taylor RE. Radiotherapy for benign disease; assessing the risk of radiation-induced cancer following exposure to intermediate dose radiation. *Br J Radiol.* 2015;88(1056):20150405.

Tables and figures

Table 1: Spontaneous keloids associated with genetic disorder

Condition	Age, years	Race	Gender	Site	Pathophysiology	Treatment	Ref. No.
Noonan syndrome	6	Caucasian	M	Third toe of the right foot	After crushed by a large stone	Surgical excision	10
Goeminne syndrome	33	Caucasian	M	Arms, chest and neck	Spontaneous	-	11
Conjunctivo-corneal dystrophy	57	Norwegian	F	Hands and fingers	Minimal trauma	Local radiation therapy	12
	22		M	Right third finger and left index finger	Spontaneous		
	15		M	Three ulnar fingers	Spontaneous		
Novel X-linked syndrome with filamin A (FLNA) mutation	36	Caucasian and Native American	M	Thighs, hips and back	Spontaneous	Topical and intralesional corticosteroids	13
Polyfibromatosis with erosive arthropathy	23	Caucasian	M	Chest, back, hands and foots	Spontaneous	Intralesional steroids and radiation therapy	14
X-linked recessive polyfibromatosis	40	Australian	M	Trunk and extremities	Spontaneous	Multiple corticosteroid injections	15
Bethlem myopathy	32	Caucasian	F	Shoulder region	Spontaneous	-	16
	50		M				
Dupuytren's disease	60	Caucasian	M	Toracic wall and anterior abdominal wall	Spontaneous	Intralesional triamcinolone and cryotherapy	17
	45	Indian	F	Shoulders, arms, thighs, legs and back	Spontaneous	-	18
	18 and his elder brother	Indian	M	Chest, abdomen, shoulders, back and thighs	Spontaneous	-	19
Rubinstein-Taybi syndrome	15	Caucasian	M	Presternal area and upper arms and back	Spontaneous	Topical corticosteroids and oral antihistamines Laser beam therapy	20
	7	Caucasian	M	Right neck, right temporal and right infraclavicular areas	Spontaneous	-	21

Table 2: Spontaneous keloids without any medical conditions

Condition	Age, years	Race	Gender	Site	Pathophysiology	Treatment	Ref. No.
Healthy Fitzpatrick skin type III	"Middle -age"	Caucasian	F	Back, Chest, Breasts	Spontaneous	Topical and intralesional corticosteroids and intralesional bleomycin UVA-1 phototherapy in a low-dosage regimen	27
Symmetrical keloids on the bilateral labia majora	59	Chinese	F	Bilateral labia majora	Spontaneous	Antibiotic treatment Surgical resection combined with postoperative radiotherapy	28
Postauricular keloid	81	Caucasian	M	Postauricular region	Spontaneous	Surgical excision	29
Bilateral idiopathic corneal keloid	2	Japanese	M	Bilateral corneal	Spontaneous	Betamethasone and tranilast eye drops Lamellar keratoplasty Corneal and conjunctival peritomy	30
Spontaneous resolution	39	Caucasian	M	Thoracic	Spontaneous	Intralesional triamcinolone	37
About a rare case	21	Caucasian	F	Back and chest	Spontaneous	Silicone gel	31
Multiple keloids	41	Caucasian	F	Back and lumbar region	Spontaneous	Cryotherapy Surgical excision with intradermal injection of triamcinolone and subsequent radiotherapy	32
Unusual histologic features	56 79	Indian Black	M F	Above the nipple	Spontaneous	-	33

Case series

Case report 1

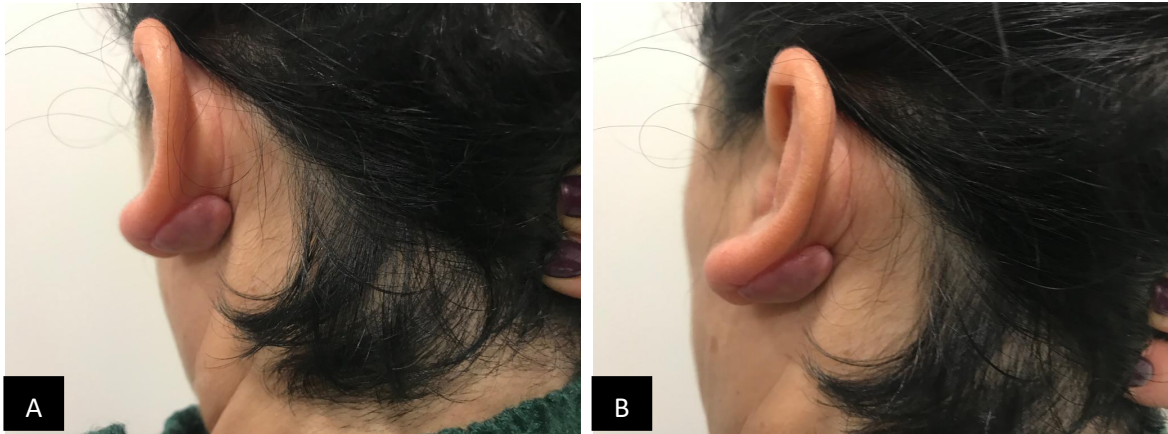

Fig. 1 (A and B) Idiopathic posterior left ear keloid before treatment.

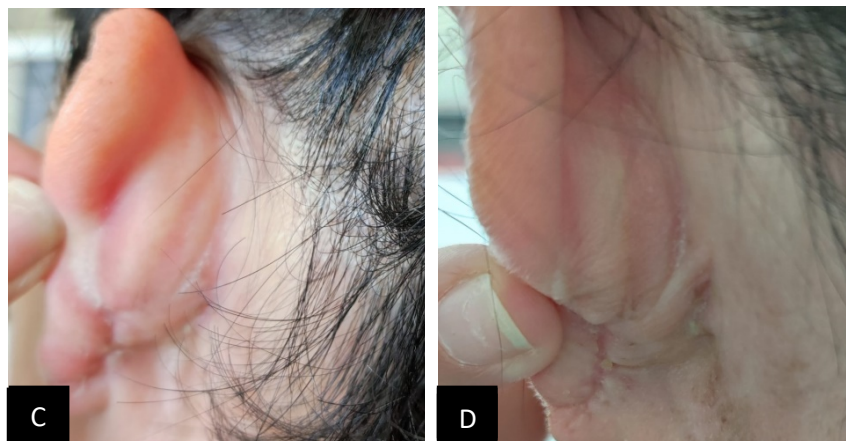


Fig. 1 (C and D) 3 months following the procedure, the patient showed no evidence of recurrence and minimal hyperpigmentation.

Case Report 2

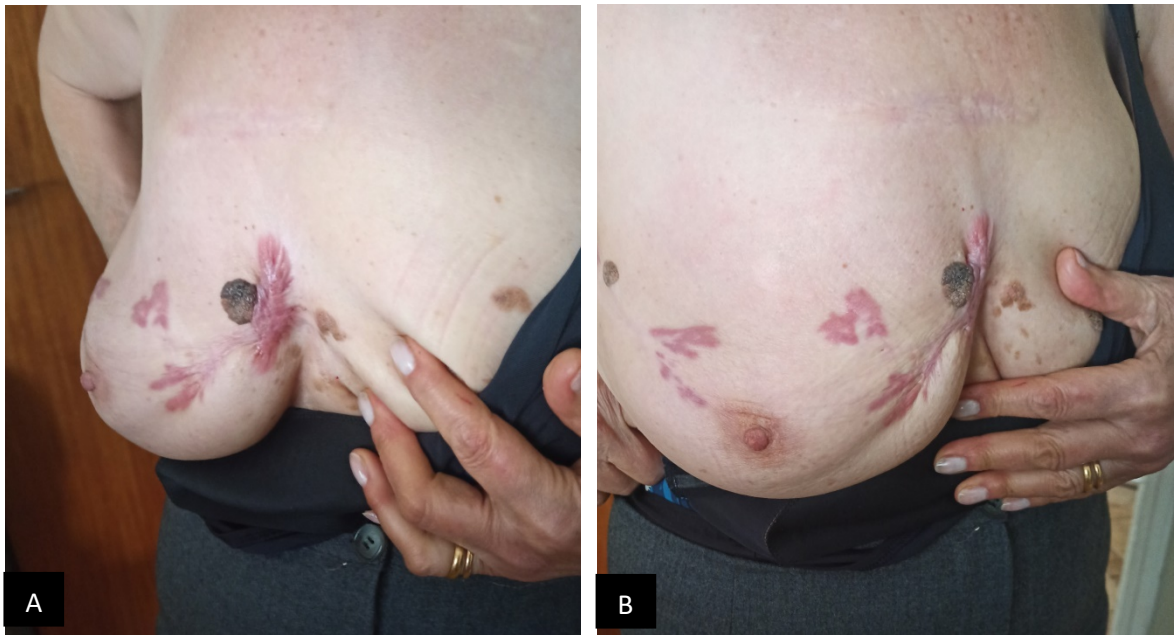


Fig. 2 (A and B) Spontaneous thoracic keloids with no desire for surgery.

ANEXOS

Scale for the Assessment of Narrative Review Articles – SANRA

Please rate the quality of the narrative review article in question, using categories 0-2 on the following scale. For each aspect of quality, please choose the option which best fits your evaluation, using categories 0 and 2 freely to imply general low and high quality. These are not intended to imply the worst or best imaginable quality.

1) Justification of the article's importance for the readership.

- The importance is not justified. _____ 0
- The importance is alluded to, but not explicitly justified. _____ 1
- The importance is explicitly justified. _____ 2

2

2) Statement of concrete aims or formulation of questions.

- No aims or questions are formulated. _____ 0
- Aims are formulated generally but not concretely or in terms of clear questions. _____ 1
- One or more concrete aims or questions are formulated. _____ 2

2

3) Description of the literature search.

- The search strategy is not present. _____ 0
- The literature search is described briefly. _____ 1
- The literature search is described in detail, including search terms and inclusion criteria. _____ 2

2

4) Referencing.

- Key statements are not supported by references. _____ 0
- The referencing of key statements is inconsistent. _____ 1
- Key statements are supported by references. _____ 2

2

5) Scientific reasoning.

(e.g., incorporation of appropriate evidence, such as RCTs in clinical medicine)

- The article's point is not based on appropriate arguments. _____ 0
- Appropriate evidence is introduced selectively. _____ 1
- Appropriate evidence is generally present. _____ 2

2

6) Appropriate presentation of data

(e.g., absolute vs relative risk; effect sizes without confidence intervals)

- Data are presented inadequately. _____ 0
- Data are often not present in the most appropriate way. _____ 1
- Relevant outcome data are generally presented appropriately. _____ 2

2

Sumscore

12

Fig. 1 SANRA - Scale

Scale for the Assessment of Narrative Review Articles – SANRA

1) **Justification of the article's importance for the readership.**

Category 2 – The importance is explicitly justified.

Page 7: "Therefore, it is intended to elaborate a clear review on reported spontaneous keloids, an extremely rare condition universally, with lack of published cases and many uncertainties to be clarified."

Page 8: "Thus, we tried to encompass a set of articles that would allow the fulfilment of a paper as comprehensive as possible, enabling a global analysis of the spontaneous keloids possible etiologies and therapies used."

2) **Statement of concrete aims or formulation of questions.**

Category 2 – One or more concrete aims or questions are formulated.

Page 7: "The purpose of this review article is to gather and summarize the reported cases of spontaneous keloids existing in the literature, organizing them according to the existence of genetic susceptibility or other associated medical conditions. In addition, an analysis will be made regarding the therapies used in this case reports as well as a brief review of the existing literature on the treatment of keloids."

3) **Description of the literature search.**

Category 2 – The literature search is described in detail, including search terms and inclusion criteria.

Page 8: "This review was conducted through a search using the online search engines PUBMED/MEDLINE and WEB OF SCIENCE. The query

("spontaneous keloids" OR "idiopathic keloids") was used (...)" "Thus, all published and accessible case reports and studies performed on humans related to spontaneous keloids were included in this paper, excluding all cases associated with trauma."

4) Referencing.

Category 2 – Key statements are supported by references.

Page 6: "Keloid is a fibroproliferative skin disorder resulting from an abnormal healing process that generates chronic wound inflammation and a continuous deposition of collagen fibers." "The distinguishing feature of keloids from hypertrophic scars is their tendency to invade the surrounding skin, extending beyond the limits of the original wound." "Keloids are usually the result of trauma but can also be associated with genetic conditions or a positive family history. Much more rarely, they can also arise spontaneously, when there is no history of trauma or surgery."

Page 7: "However, despite this variety of therapeutic options, keloids remain highly refractory lesions, requiring a search for more effective therapies."

Page 14: "Several studies have shown that surgical excision used as monotherapy is associated with a high recurrence rate, which can vary between 50-80%, and should be mostly avoided."

5) Scientific reasoning.

Category 2 – Appropriate evidence is generally present.

Page 10: "An observational case-control study involving 259 Syrians individuals with keloids showed that 34 of them developed keloids spontaneously, mostly

on the shoulders and pre-sternal region. In addition, it also revealed a statistically significant association between this and type A blood group (34). Another observational case-control study involving 88 Iraqi patients with keloids found that 34% of them had no previous history of trauma, having grown the keloids mostly solitary and in the upper part of the body. (35)"

Page 14: "A retrospective study analyzed 124 patients with 250 keloids who were treated with postoperative radiotherapy and showed that after a median follow-up period of 40 months, the overall recurrence rate for all lesions was 5.6%. (41)"

6) Appropriate presentation of data.

Category 2 – Relevant outcome data are generally presented appropriately.

Page 14: "A retrospective study analyzed 124 patients with 250 keloids who were treated with postoperative radiotherapy and showed that after a median follow-up period of 40 months, the overall recurrence rate for all lesions was 5.6%. (41) The group of patients with lesions treated with 20 Gy had a recurrence rate of 1.6% while the group treated with <20 Gy had 9.6% (with an odds ratio of 0.16 (confidence interval 0.036-0.75, P = 0.02). (41)"



Guide for Authors

Aims and scope

Please note: failure to follow our detailed instructions to authors may influence the decision to accept or reject the manuscript and will adversely affect time to publication.

Journal scope

The *Journal of Plastic, Reconstructive & Aesthetic Surgery* is the official journal of the British Association of Plastic, Reconstructive and Aesthetic Surgeons (BAPRAS). Its objective is to publish original articles about developments in all areas related to plastic, reconstructive and aesthetic surgery and to provide a forum for correspondence and discussion. Significant papers on any aspect of plastic surgery are invited for publication. These include operative procedures with an emphasis on outcome, technical innovations, clinical or laboratory research, letters to the Editor and review articles.

Editorial policy

Original contributions are welcomed from any country, but the prose used in manuscripts must conform to acceptable English usage. The text must be clear, logical and concise. In assessing a manuscript for publication the Editor will also consider its originality, educational value and validity. Recommendations regarding major rearrangements or corrections may be offered to help authors re-write their submission in a way that is acceptable to the journal. The Editor reserves the right to make editorial and literary changes and accepted articles may be subject to further copy-editing to conform to journal style.

This journal operates a single blind review process. All contributions will be initially assessed by the editor for suitability for the journal. Papers deemed suitable are then sent to a minimum of two independent expert reviewers to assess the scientific quality of the paper. The Editor is responsible for the final decision regarding acceptance or rejection of articles. The Editor's decision is final. More information on types of peer review.

As reviewers assist in their own time, without remuneration, authors can greatly assist the process by submitting correctly formatted papers in accordance with the following guidelines.

Language editing services

Authors who require information about language editing and copyediting services pre- and post-submission please visit <https://www.elsevier.com/languagepolishing> for more information. Use

of an English-language editing service is not mandatory, and will not guarantee acceptance or preference for publication. Elsevier neither endorses nor takes responsibility for any products, goods or services offered by outside vendors through our services or in any advertising. For more information, please refer to our Terms & Conditions: <https://www.elsevier.com/termsandconditions>.

Online submission

All material should be submitted through the online submission and review system (<https://www.editorialmanager.com/JPRAS/default.aspx>). All text, including references, figure legends and tables should be prepared in a single file. Illustrations should be supplied as separate files.

Authorship

All authors should have made substantial contributions to all of the following:

- (1) the conception and design of the study, or acquisition of data, or analysis and interpretation of data
- (2) drafting the article or revising it critically for important intellectual content
- (3) final approval of the version to be submitted.

Acknowledgements

All contributors who do not meet the criteria for authorship as defined above should be listed in an acknowledgements section. Examples of those who might be acknowledged include a person who provided purely technical help, writing assistance, or a department chair who provided only general support. Authors should disclose whether they had any writing assistance and identify the entity that paid for this assistance.

Conflict of interest

Authors

At the end of the text, under a subheading 'Conflict of interest statement', all authors must disclose any financial and personal relationships with other people or organisations that could inappropriately influence (bias) their work. Examples of potential conflicts of interest include employment, consultancies, stock ownership, honoraria, paid expert testimony, patent applications/registrations, and grants or other funding. If the authors have no conflicts of interest, they should state 'none'.

Reviewers

Reviewers must disclose to the Editor any conflicts of interest that could bias their opinions of the manuscript, and they should disqualify themselves from reviewing specific manuscripts if they believe it to be appropriate. Reviewers must state explicitly whether conflicts do or do not exist. Reviewers must not use knowledge of the work, before its publication, to further their own interests.

Role of the funding source

All sources of funding should be declared as an acknowledgement at the end of the text. Authors should declare the role of study sponsors, if any, in the study design, in the collection, analysis and interpretation of data; in the writing of the manuscript; and in the decision to submit the manuscript for publication. If the study sponsors had no such involvement, the authors should so state.

Open access

This journal offers you the option of making your article freely available to all via the ScienceDirect platform. To prevent any conflict of interest, you can only make this choice after

receiving notification that your article has been accepted for publication. The fee of \$3,300 excludes taxes and other potential author fees such as color charges. In some cases, institutions and funding bodies have entered into agreement with Elsevier to meet these fees on behalf of their authors. Details of these agreements are available at <https://www.elsevier.com/fundingbodies>. Authors of accepted articles, who wish to take advantage of this option, should complete and submit the order form (available at <https://www.elsevier.com/locate/openaccessform.pdf>). Whatever access option you choose, you retain many rights as an author, including the right to post a revised personal version of your article on your own website. More information can be found here: <https://www.elsevier.com/authorsrights>.

Standardized reporting guidelines

JPRAS is committed to standardized reporting of clinical trials, meta-analyses, and other studies as follows:

- Cohort studies, and patient series: Authors should adhere to the STROBE guidelines (<http://www.strobe-statement.org/>) and indicate this in the manuscript.
- Diagnostic measure research: Authors should adhere to STARD guidelines (<http://www.stard-statement.org>) and indicate in the Materials and Methods section of the manuscript that they have done so.
- Systematic reviews and meta-analyses: Authors should adhere to the PRISMA guidelines (<http://www.prisma-statement.org>) and indicate in the Materials and Methods section of the manuscript that they have done so.
- Meta-analyses will follow the PRISMA guidelines, be hypothesis driven to address a specific aspect of a topic, include sufficient (ideally at least 10) Level I and II evidence studies that can be supplemented with comparative Level III studies, and not include Level IV studies. The result should clarify the issue addressed.
- A repeat meta-analysis should follow the original study by at least 5 years, analyze at least 50% more data, and follow the above guidelines.
- A worthy systematic review will follow the PRISMA guidelines, be hypothesis driven, focus on a specific aspect of a topic, and may include low level evidence. The results should clarify the issue addressed.
- Randomized clinical trials: Authors should adhere to CONSORT guidelines (<http://www.consort-statement.org>) and indicate in the Materials and Methods section of the manuscript that they have done so.
- JPRAS has adopted the proposal from the International Committee of Medical Journal Editors (ICMJE: see <http://www.icmje.org>) which require, as a condition of consideration for publication of clinical trials, registration in a public trials registry. Trials must register at or before the onset of patient enrolment. The clinical trial registration number (ISRCTN) should be included at the end of the article summary. For this purpose, a clinical trial is defined as any research project that prospectively assigns human subjects to intervention or comparison groups to study the cause-and-effect relationship between a medical intervention and a health outcome. Studies designed for other purposes, such as to study pharmacokinetics or major toxicity (e.g. phase I trials) would be exempt. Further information can be found at <http://icmje.org>

Ethics

The results of human and/or animal studies will only be accepted for publication in the *Journal of Plastic, Reconstructive & Aesthetic Surgery* if it is made clear that investigations were carried out to a high ethical standard. Formal and documented ethical approval from an appropriately constituted research ethics committee should be obtained for all studies involving people, medical records, and anonymised human tissues. All such studies should conform to the World

Medical Association Declaration of Helsinki (June 1964) and subsequent amendments (<https://www.wma.net/what-we-do/medical-ethics/declaration-of-helsinki/>) and manuscripts should include a statement that the research protocol was approved by the local Ethical Committee or equivalent.

Animal experiments require full compliance with local, national, ethical, and regulatory principles, and local licensing arrangements and the journal will not accept papers for publication if doubts exist over the standards of care and humanity shown to experimental animals. For this reason a clear statement of the care principles used should be included in the text.

Guidelines on publication ethics adhered to by this journal can be found on the Committee on Publication Ethics (COPE) website at <http://www.publicationethics.org>.

Covering letter

Manuscripts must be accompanied by a covering letter stating that the current "Guide for Authors" has been read, thereby indicating compliance with those instructions and acceptance of the conditions posed. The letter should state that the authors have seen and agreed to the submitted version of the paper, and bear responsibility for it; that all who have been acknowledged as contributors or as providers of personal communications have agreed to their inclusion; that the material is original; and that it has been neither published elsewhere nor submitted for publication simultaneously. In addition the letter should state that if accepted, the paper will not be published elsewhere in the same or similar form, in English or in any other language, without written consent of the copyright holder.

Preparation of manuscripts

Failure to submit papers in accordance with these instructions will result in the return of the manuscript for correction before it is sent out for review. All copy must be typed double spaced, including text, bibliographies, figure legends and tables. Use a standard, easy-to-read wordprocessor font such as Times New Roman or Arial. All pages should be numbered in the bottom right corner or bottom centre. Papers should be set out as follows: title page, summary, keywords, text, acknowledgements, references, figure legends, tables.

Main article types

- **Original research articles** should generally be no more than 3000 words in length, with 40 references and 16 figures/illustrated images/ tables. Please note that composite figures count as individual items.
- **Review papers** should be no more than 4000 words, with 80 references and 16 figures/illustrated imaged/tables. Please note that composite figures count as individual items.

Other article types

• **Please note, case reports and short reports are no longer accepted as an article type. Case Reports may be submitted to JPRAS OPen, at <https://www.editorialmanager.com/JPRASO/default.aspx>**

• **Communications and correspondence:** letters for publication should be no more than 800 words in length, with five references and two tables/figures. If the letter is in response to a published article, then the article should be included in the reference list.

Online-only publication

Due to the large volume of submissions to the journal, extended datasets, appendices (see 'Supplementary data' below), and items of correspondence may be considered for online-only

publication at the Editor's discretion. Authors will be informed if their submission is selected to appear online only.

Title page

The title page should give the following: (1) title of the article

(2) initials and name of each author

(3) name and address of the department or institution to which the work should be attributed

(4) the name, address, telephone, fax and e-mail details of the author responsible for editorial correspondence

(5) details of any meeting at which the work was presented, wholly or in part.

Summary and keywords

The article summary should consist of no more than 250 words. The journal does not demand structured abstracts, but the summary should briefly describe the background and purposes of the study, the subjects studied and the methods used, the main findings (including specific data and statistical analysis) and the conclusions. Please bear in mind that the summary will be visible through all the major abstracting services (such as MEDLINE and Scopus) and should therefore be an accurate and concise outline of the paper. Four to six keywords should be provided at the end of the summary.

Text

Headings should be appropriate to the nature of the paper. Research papers should usually be split into sections under the headings: Introduction, Materials/Patients and Methods, Results and Discussion. Other headings may be appropriate depending on the nature of the paper; the proper use of headings enhances clarity and readability. Normally only two categories of heading should be used, which should be clearly distinguished.

Drug/device names: Use generic names of drugs, suture materials and instruments whenever possible. Give the trade name in brackets after the generic or approved name, followed by manufacturer, city, state (if US), and country. Proprietary names should be capitalised.

Abbreviations should be avoided in the title and summary. Explain abbreviations when they first occur in the text.

Numbers: use SI units throughout. Spell out the numbers one to ten except when used for units of measurement (mass, time, length); for numbers over ten use numerals except when starting a sentence. Do not give percentages if the total number in the sample is less than 50. Percentages greater than ten should be rounded to the nearest whole number. Numerical data should be analysed by appropriate statistical methods. When evaluating a manuscript, the Editor and statistical referees will consider the design of the study, the presentation of the data, the analysis of the data and the interpretation of the results. The use of standard deviation and standard error should be clearly distinguished. The statistical test(s) used should be stated clearly in the 'Methods' section of the paper. Statistical significance should not be confused with clinical significance. In particular, 'negative' findings should be interpreted through the use of confidence intervals. Authors should beware of placing undue emphasis on secondary analyses, especially when they are suggested by an inspection of the data.

Tables

These should be double-spaced, and contain only horizontal rules. Format tables with tabs rather than spaces, or prepare them as tables in Microsoft Word. Do not submit tables as photographs. A short descriptive title should appear above each table and any footnotes,

suitably identified, below. Care must be taken to ensure that all units are included. Ensure that each table is cited in the text.

Figures

Figures should be submitted online as separate files. The minimum resolution for high quality reproduction is 300 dpi. For detailed instructions on the preparation of electronic artwork, consult the Artwork Instructions to Authors: <https://www.elsevier.com/artworkinstructions>. Permission to reproduce illustrations from other sources should always be obtained before submission, and details included with the legend. The journal is published in full colour (in print and online) at no charge to authors, so colour photographs should be submitted wherever possible. Photographs must be in sharp focus with good contrast and should not be altered or retouched in any way. 'Before' and 'after' photographs of patients should be standardised in terms of size, position and lighting. Provide scale bars on photomicrographs rather than stating the magnification in the legend. Legends are required for figures and should be included as part of the manuscript. All figures should be numbered in a single sequence.

Patient confidentiality: where illustrations include individuals of whatever age who are recognizable or whose identity may be deduced from the context, written consent must be obtained for publication. All identifying features not considered relevant to the text should be obscured.

Supplementary data (including multimedia and video)

The journal accepts electronic supplementary material to support and enhance your scientific research. Supplementary files allow the author to submit supporting applications, movies, animation sequences, high-resolution images, background datasets, sound clips and more, which will be published online alongside the electronic version of your article. In order to ensure that your submitted material is directly usable, please ensure that data is provided in one of the recommended file formats (for detailed guidance on formats for supplementary files go to <https://www.elsevier.com/fileformats>).

References

Please ensure that you include all relevant references to previous articles in the *Journal of Plastic, Reconstructive & Aesthetic Surgery*. The accuracy of references is the responsibility of the authors. Limit citations to those that are essential to the study. It is not necessary or appropriate to quote each and every historical reference unless there is a specific point to be made. References derived from computer literature searches should not be cited unless they have been read and contribute specifically to the discussion.

References should be cited in the text in numerical order, not alphabetically, and be indicated in the text by superscript numbers, e.g. 1, 2 or 1-4. The reference list should be typed double-spaced and in numerical order. If there are more than six authors list only the first three followed by 'et al.' Journal titles should be abbreviated according to Index Medicus (see <http://www.nlm.nih.gov/tsd/serials/lji.html>). Internet resources should have their accessibility verified and all URLs should be checked again at proof stage.

Examples

Journal article: Frame JD, Frame JE. Modifying integra as a regeneration template in deep tissue planes. *J Plast Reconstruct Aesthet Surg* 2006;59;460-4.

Book chapter: Lister GD. Skin flaps. In Green DP, ed. Operative Hand Surgery. 3rd ed. New York: Churchill Livingstone, 1993: 1741-1823.

Book: Mathes SJ, Nahai F. Reconstructive Surgery: principles, anatomy, and technique. New York: Churchill Livingstone, 1997.

Internet resource: International Committee of Medical Journal Editors. Uniform requirements for manuscripts submitted to biomedical journals. <http://www.icmje.org>. [Accessibility verified March 21, 2008]

Data References

This journal encourages you to cite underlying or relevant datasets in your manuscript by citing them in your text and including a data reference in your Reference List. Data references should include the following elements: author name(s), dataset title, data repository, version (where available), year, and global persistent identifier. Add [dataset] immediately before the reference so we can properly identify it as a data reference. The [dataset] identifier will not appear in your published article.

Copyright

Contributions are accepted on the understanding that they have not been submitted simultaneously to another Journal and have not been published elsewhere. Dual publication or redundant publication is unethical. Redundant publication occurs when two or more papers, without full cross reference, share the same hypothesis, data, discussion points, or conclusions. For more details please refer to the COPE guidelines on <http://www.publicationethics.org>.

Contributions will become the property of the British Association of Plastic, Reconstructive and Aesthetic Surgeons and the copyright on each paper published must be assigned to the Association by all of the authors (see below).

Upon acceptance of an article, authors will be asked to sign a 'Journal Publishing Agreement' (for more information on this and copyright see <https://www.elsevier.com/copyright>). Acceptance of the agreement will ensure the widest possible dissemination of information. An e-mail will be sent to the corresponding author confirming receipt of the manuscript together with a 'Journal Publishing Agreement' form or a link to the online version of this agreement. Subscribers may reproduce tables of contents or prepare lists of articles including abstracts for internal circulation within their institutions. Permission of the Publisher is required for resale or distribution outside the institution and for all other derivative works, including compilations and translations (please consult <https://www.elsevier.com/permissions>).

If excerpts from other copyrighted works (e.g. illustrations and tables) are included, the author(s) must obtain written permission from the copyright owners and credit the source(s) in the article. Elsevier has preprinted forms for use by authors in these cases: please see <https://www.elsevier.com/permissions> (<https://www.elsevier.com/permissions>). Borrowed material should be acknowledged in the legends in this style: 'Reproduced with the permission of ... (publishers/journal) from (reference)'.

Graphical abstracts

The Journal encourages a Graphical Abstract to be submitted alongside the manuscript for consideration for publication, as it draws more attention to the online article. The graphical abstract should summarize the contents of the article in a concise, pictorial form designed to capture the attention of a wide readership. Authors wishing to submit a Graphical Abstract

alongside their manuscript at submission should use the JPRAS-preferred template available [here](#) and upload the file as a separate submission item (Preferred file types: TIFF, EPS, PDF or MS Office files). Authors should also be informed that if their manuscript is accepted following peer-review and they have not submitted their own accompanying Graphical Abstract, the JPRAS editors reserve the right to create the Graphical Abstract on their behalf. This would be done by the JPRAS stable of designers/artists to host with the accepted article on ScienceDirect and for promotional use, particularly across social media.

Funding body agreements and policies

Elsevier has established agreements and developed policies to allow authors who publish in Elsevier journals to comply with potential manuscript archiving requirements as specified as conditions of their grant awards. To learn more about existing agreements and policies please visit <https://www.elsevier.com/fundingbodies>.

Proofs

One set of page proofs in PDF format will be sent by e-mail to the corresponding author, which they are requested to correct and return within 48 hours. Elsevier now sends PDF proofs which can be annotated; for this you will need to download Adobe Reader version 7 available free from Adobe (<http://www.adobe.com/products/acrobat/readstep2.html>) . Instructions on how to annotate PDF files will accompany the proofs. The exact system requirements are given at the Adobe (<http://www.adobe.com/products/acrobat/acrrsystemreqs.html#70win>) site.

If you do not wish to use the PDF annotations function, you may list the corrections (including replies to the Query Form) in an e-mail. Please list your corrections quoting line number. If, for any reason, this is not possible, then mark the corrections and any other comments (including replies to the Query Form) on a printout of your proof and return by fax, or scan the pages and e-mail, or by post.

Please use this proof only for checking the typesetting, editing, completeness and correctness of the text, tables and figures. Significant changes to the article as accepted for publication will only be considered at this stage with permission from the Editor. We will do everything possible to get your article published quickly and accurately. Therefore, it is important to ensure that all of your corrections are sent back to us in one communication: please check carefully before replying, as inclusion of any subsequent corrections cannot be guaranteed. Proofreading is solely your responsibility. Note that Elsevier may proceed with the publication of your article if no response is received.

Offprints

The corresponding author, at no cost, will be provided with a personalized link providing 50 days free access to the final published version of the article on ScienceDirect (<http://www.sciencedirect.com>). This link can also be used for sharing via email and social networks. For an extra charge, paper offprints can be ordered via the offprint order form which is sent once the article is accepted for publication. Both corresponding and co-authors may order offprints at any time via Elsevier's WebShop (<http://webshop.elsevier.com/myarticleservices/offprints>). Authors requiring printed copies of multiple articles may use Elsevier WebShop's 'Create Your Own Book' service to collate multiple articles within a single cover (<http://webshop.elsevier.com/myarticleservices/booklets>).